

veterinary technology for life

Eickemeyer®

www.eickemeyer.co.uk

Telephone 020 8891 2007

Bone Collector Set

Fast and reliable spongiosa removal from small animals

**With
Specialist
Article
by Dr. Daniel
Koch**




BONE COLLECTOR / BONE GRAFT HARVESTING SET – COMPONENTS AND CHARACTERISTICS

New set for fast and reliable spongiosa removal from small animals.

Spongiosa grafts are usually removed after drilling open the cortex using a curette. The EICKEMEYER® Bone Collector is a new, technically simple, fast and safe procedure for bone marrow removal using a special drill bit. The set consists of an adapter to be placed on the drill with AO coupling, 3 drill bits or collection sleeves with collection container, a slider for emptying the spongiosa, an open-end wrench for securely fixing the drill bit to the adapter, a storage and sterilization module for the sterilisation room and two KIRSCHNER drill wires.

The advantages are time, as the sample collection after the skin incision takes only a few seconds, and there is no need to use tissue retractors, so that only a small amount of iatrogenic trauma occurs.



197312



197313



197314



197315



197316



197317



197318

BONE COLLECTOR / BONE GRAFT HARVESTING SET – ITEM LIST

Bone Collector / Bone Graft Harvesting Set		
Item No.	Description	Quantity
197310	Complete set, consisting of:	
197311	Bone Collector Storage and Sterilization Module, without instruments	1
197312	Bone Collector Drill Bit Ø 4 mm, AO Quick Coupling	1
197313	Bone Collector Drill Bit Ø 5 mm, AO Quick Coupling	1
197314	Bone Collector Drill Bit Ø 6 mm, AO Quick Coupling	1
197315	Bone Collector Drill Adapter	1
197316	Bone Collector open-end Wrench	1
197317	Bone Collector Slider	1
197318	Bone Collector KIRSCHNER Drill Wire, Ø 1.6 x L 100 mm, trocar	2

New method for removing cancellous bone from small animals

Introduction

Autologous bone marrow is still the best substitute in veterinary surgery when it comes to bone replacement (Cornu et al., 2009). It combines all the desired properties for building new bone. Even if the number of transferred cells is rather small, the bone trabeculae still contain a large number of osteoblasts, which then stimulate new bone formation with the help of local cytokines.

A correctly removed and inserted bone marrow transplant provides a pre-existing structural framework to which new bone substrate can then attach on the recipient side, this is known as

osteoconduction. The simultaneous onset of local blood circulation, stimulated by open bone ends or those opened by the surgeon, as well as careful handling of the local blood vessels, allows the platelets and growth factors (IGF-1, PDGF, TGF-Beta) to have an osteopromotive effect (Kraus, 2012).

The areas of application of autologous bone marrow are diverse. For example in practical orthopaedics such as bridging bone defects after fractures, after complicated corrective osteotomies or filling bone cysts. It is also perfect after a Tibial Tuberosity Advancement (TTA) operation, to treat a cruciate ligament tear,

BONE COLLECTOR / BONE GRAFT HARVESTING SET – SPECIALIST ARTICLE

the resulting gap being filled; and of course in the case of arthrodesis, where the joint that is to be immobilized and freed from cartilage is filled with the bone marrow. Popular and productive locations for cancellous bone removal are the proximal humerus, the proximal tibia or the iliac wing (Penwick et al., 1991).

The usual technique for removal is to drill out the bone with a Steinmann nail, remove it with a curette and temporarily store it in a moist swab or in the plunger of a syringe (Kraus, 2012). Here we present a new technique with a special implement, which drills into the cortex in a single step, collects the cancellous bone and can therefore harvest any amount of bone marrow without loss.

Description of the method

The required instruments (Delos Medical, Neuhausen ob Eck, Germany) consist of an adapter with a Synthes coupling to be placed on the drill, 3 different sized drill bits with a collection container, a wrench to securely fix the drill bit on the adapter, and a slider to empty the cancellous bone as well as two KIRSCHNER drill wires for loosening any stuck cancellous bone (Fig. 1).




Fig. 1: Instruments for bone marrow collection, from left to right: adapter, 3 drill bits, wrench, slider, KIRSCHNER wire.

Case Study

The patient was a 4-year-old female greyhound. Approximately 1.5 years earlier, she suffered a tear in the medial oblique collateral ligament of the right carpus in a fall. The reconstruction using ligament replacement only, took place around 10 weeks after unsuccessful splint therapy. The ligament replacement tore after 4 months, so that over time osteoarthritis developed, after which the dog no longer put any weight on her leg. It was decided to perform Pancarpal Arthrodesis.

The proximal tibia was selected for the removal of the cancellous bone. Once the dog was placed under anaesthesia, both the tibia

and right carpus were aseptically prepared and draped. The first surgical step was a 1 cm incision in the skin over the medial proximal tibia. The adapter and the middle drill bit eyelet were attached to the drill. While cooling with sterile saline solution, the cortex was drilled at a speed of 1.200 rpm and the drill bit was driven into the endosteum of the tibia under careful pressure (Fig. 2). A mix of cortex and cancellous bone collected in the shaft of the drill bit which was then unscrewed (Fig. 3), the collected bone marrow was placed in a moist swab using the slider (Fig. 4 + 5). From there, about 30 minutes later, the cancellous bone was moved into the radiocarpal joint, which had been freed from cartilage and prepared for vascularity using osteostixis, after which it was plated (Fig. 6).

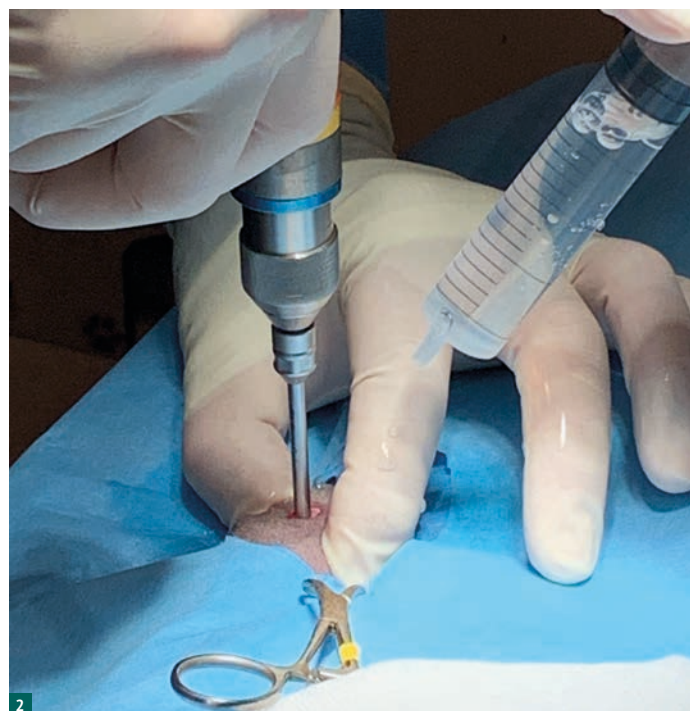


Fig. 2: Drilling out the cortex using a drill.

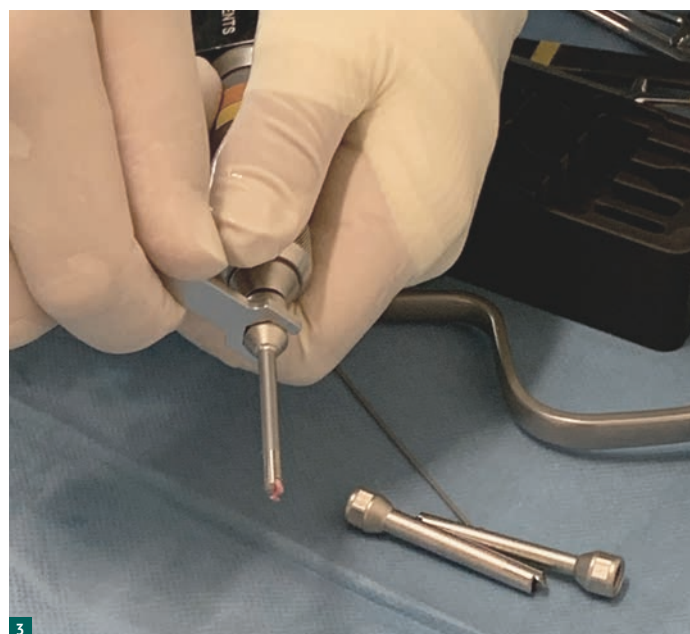

Fig. 3: The drill bit is unscrewed from the adapter using the wrench.

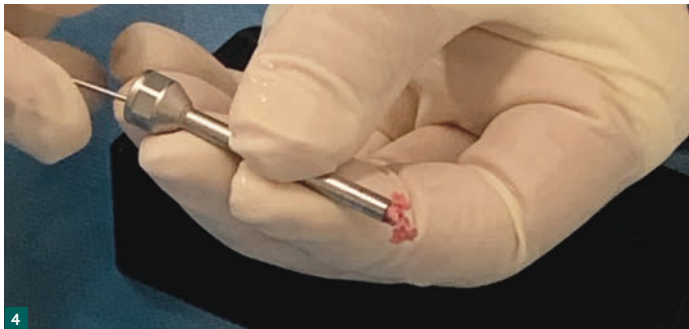


Fig. 4: The cancellous bone obtained can be pushed out of the drill bit using the slider.

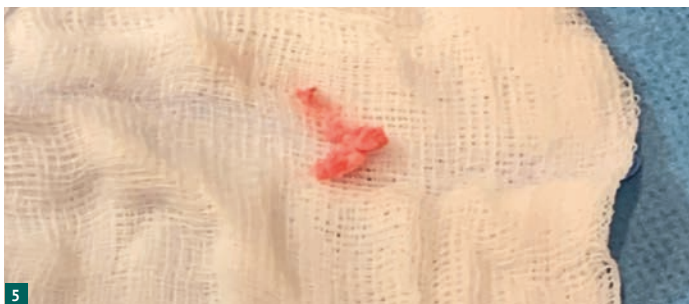

Fig. 5: The cancellous bone is stored in a wet swab.

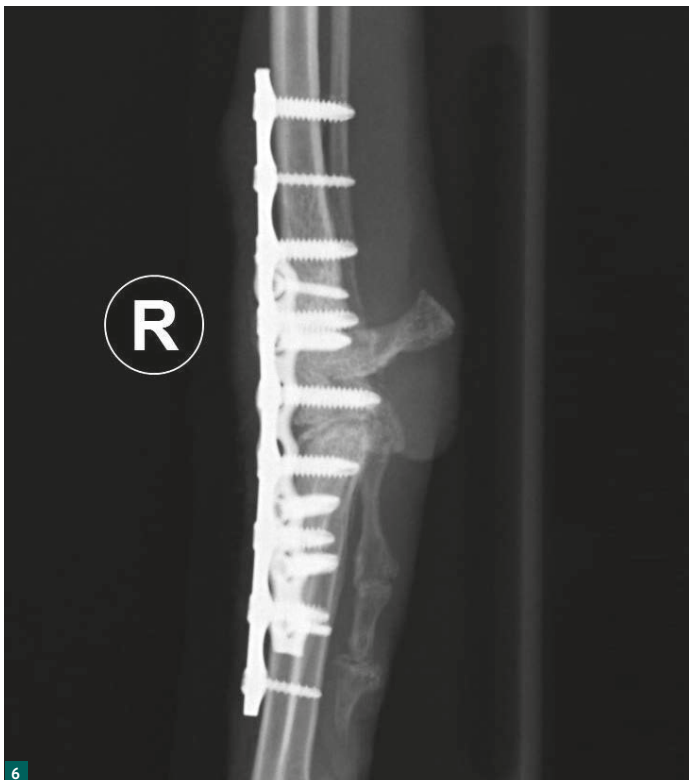

Fig. 6: Postoperative X-ray image (LL image) of the pancarpal arthrodesis using two angle-stable plates.

process. With the established technique, it can be difficult to find the cortical opening with the curette, which is particularly the case with a broad, covering of muscle layers. Since the cancellous bone is collected in the drill bit, there is no loss of harvested bone. The one disadvantage is that a little bit of the cortex is captured and this has a slightly less osteoinductive effect than cancellous bone.

If the cancellous bone harvested through the new drill bit does not meet the requirements, a new harvest could be carried out from another location or – as in the existing method – a curette is inserted into the endosteum to obtain additional bone marrow or the larger diameter drill bit can be chosen. None of this was necessary in our case because the joint space that needed to be filled was quite small.

The new method delivers results that are very easy to implement clinically and impresses with its easy handling, rapid cancellous bone collection and little iatrogenic trauma.

Literature

1. Cornu O., Schubert T., Libouton X., Manil O., Godts B., Van Tomme J., Banse X., Delloye C. (2009): Particle size influence in an impaction bone grafting model. Comparison of fresh-frozen and freeze-dried allografts. *J Biomech* 42: 2238-2242.
2. Innes J. (2014): Bone grafting in small animal orthopaedic surgery. *In Practice*: 173-181.
3. Kraus K. H. (2012): *Bone Grafts and Substitutes. Veterinary Surgery Small Animal.* Tobias K. M. und Johnston S. A. St. Louis, Elsevier Saunders: 676-684.
4. Penwick R. C., Mosier D. A., Clark D. M. (1991): Healing of canine autogenous cancellous bone graft donor sites. *Vet Surg* 20: 229-234.

Author's address

Daniel Koch, Dr. med. vet. ECVS
Rhyäcker 7
CH-8253 Diessenhofen
www.dkoch.ch

Original article in a similar form appeared in the magazine
KLEINTIERMEDIZIN, Issue 5-2023, pp. 6–9

© Copyright – text and photos by the author



Dr. Daniel Koch

Specialist in small animal surgery; DECVS

Specialist in small animal surgery; DECVS;
Specialisations: joint surgery, osteosynthesis, airway obstruction and dental treatment; Research areas: brachycephalic syndrome, knee joint of the dog.

Discussion

Compared to the previous technique of opening the cortex with a Steinmann nail and extracting cancellous bone using a curette, the following advantages arose with the new technique. The extraction took approximately 5 seconds after the skin incision, any damage to soft tissue could be avoided because the removal was a singular

NOTES

[illegible]

